# California Department of Fish and Wildlife
# Livestock Depredation Investigation

**Investigation ID (Date(yymmdd)-County:** Siskiyou-01

**Report Prepared by:** Richard Callas **Date Prepared:** 11/18/2015

**Date CDFW Notified:** 11/10/2015 **Notified by:** [redacted]

**Date Investigated:** 11/11/2015 **Time On/Off Scene:** 0530 hours/~1315 hours

**Primary Investigators:** Richard Callas (CDFW) / Scott Stiles (USDA Wildlife Services)

**Others Present:** [redacted]

**Livestock Owner:** [redacted] **Property Owner:** [redacted]

**Livestock Owner Contact Information:** [redacted]

**General Location: Latitude:** [redacted] **Longitude:** [redacted]

**Terrain Features and Vegetation Type:** grassy meadow surrounded by conifer forest

Background

This incident occurred approximately [redacted] in Siskiyou County on property owned by [redacted]. At the time of the incident, this property was grazed by cattle owned by [redacted]. [redacted] reported that on 11/10/2015, at approximately 0845 hours, he and several employees were gathering cattle from horseback. At that time, one of his employees observed 5 wolves feeding on a dead calf in a meadow, hereafter referred to as the carcass site. The employee photographed the calf carcass (Figure 2) and one of the wolves (Figure 3). The wolves reportedly left the calf carcass when approached by his employee and [redacted] observed at least one of those animals at that time. The riders continued to gather cattle and returned to the carcass site about 30 minutes later and were unable to locate the carcass. They found an area of blood approximately 1 foot in diameter and two hind legs presumably from a single calf in a small island of conifers within the meadow about 100 yards from carcass site.

The riders gathered approximately 160 adult cows and approximately 40 calves on the day of the incident. [redacted]'s cattle had occupied the meadow for about 30 days prior to this investigation and during that time no other livestock were known to have died. His cattle were checked approximately every 3 days and prior to 11/10/2015, had most recently been checked on 11/07/2015. [redacted] planned to gather and remove the remaining cattle from the property on 11/12/2015.

## Scene Details

**Scene Modified Before Arrival of Investigators?** Yes—livestock owner and employees searched for the dead calf and collected two hind legs that presumably were from a single calf on the day of the incident. The calf legs were given to R. Callas on 11/11/2015.

**Livestock Behavior:** [redacted] reported the cattle being unusually "bunched up" when the riders arrived to gather them for transport on the day of the incident.

**Tracking Conditions and Substrate:** Grassy meadow with occasional areas of bare ground due to cattle trails.

**Evidence of Wolf Presence:**

Notes of site inspection conducted on 11/11/2015:

- At approximately 0530 hours, Scott Stiles and Richard Callas arrived at the meadow where the calf carcass was found the previous day and parked approximately 0.20 miles southeast of the carcass site. Mr. Stiles played a recording of a single wolf howling. Within several seconds, multiple wolves vocalized from across the meadow. Scott played additional vocalizations of a pair of wolves, wolf pups, and a rabbit call. One of the wolves came within an estimated 100 yards of us (based on the volume of its vocalizations) in the dark and barked and howled repeatedly. No wolves were visible at that time.

- At approximately 0645 hours, we drove to the opposite side of the meadow to the general area where we heard the wolves vocalizing that morning and observed 3 black wolves. I photographed 3 wolves near the western edge of the meadow (Figures 4-6) and recorded a short video of one individual vocalizing.

- At approximately 0700 hours, we left the meadow to meet [redacted] and returned to search for the calf and physical evidence of wolf presence.

**Evidence of Predation/Scavenging:** (see Figure 7 for a scene overview and Figures 8-9 for photographs of the general area where the calf carcass was discovered)

- Two areas of blood, each about 1 foot in diameter, and several bloody bone fragments were found near the site where the calf carcass was discovered on 11/10/2015 (Figures 10-13).

- Presumptive wolf scats containing what appeared to be cattle hair were collected in the vicinity of where the calf carcass was found (Figures 14-15).

- While searching for additional calf remains on 11/11/2015, the carcass of an adult cow was found (Figures 16-20). The skin and muscle tissue of this animal was almost completely absent

from the carcass. This animal appeared to have died fairly recently (estimated at <2 weeks) based on the relatively fresh appearance of tissue remaining on the carcass. It did not smell rotten, although the rate of decay was likely slowed by relatively cool temperatures and conifers that partially shaded the carcass. Apparent rumen contents were located about 15 yards from the carcass and were dry (Figures 21-22).

- Approximately 50 yards south of the cow carcass, a rock weighing about 50 pounds had been recently moved, exposing bare ground, and a pile of woody debris had been disturbed. Several limbs about 2 inches in diameter, portions of a log were freshly broken, and several linear scrapes were visible on a log that may have been made by a hoof (Figures 23-26). No substantial evidence of ground disturbance that might have been caused by a struggle was found. A presumptive wolf track was found within about 30 yards of this site (Figures 27-28).

**Livestock Description:**

**Live Animal:** ___ **Carcass:** _X__

**Estimated Date/Time of Death/Injury:**

Calf - Death likely occurred on or about 11/10/2015, based on the appearance of remains collected, photograph of the carcass, and assessment of the carcass condition when observed by [redacted].

Cow – Date of death unknown, but may have occurred <2 weeks prior to this investigation, based on the state of carcass decomposition.

**Type of Livestock:** Cattle

**Sex:** Cow = female; Calf = unknown

**Age:** Cow = adult; Calf = 14-30 days

**Weight:** Cow =~1,000 lbs.; calf = ~100 lbs.

**Carcass Disturbed by Humans Before Arrival?** Cow = no; Calf = Yes (rear legs collect by [redacted])

**Carcass Protected Since Discovery:** Calf remains found on 11/10/2015 were collected and provided to CDFW. The cow carcass discovered on 11/11/2015, was not protected or collected.

**Positions of Carcasses:** Carcasses were substantially consumed (see attached photographs)

**Carcass Description:**

- Calf – Only the lower portions of both rear legs (Figure 29) and a few bone fragments were collected.

- Cow – Partially articulated skeleton was found. Little muscle tissue was present. The ends of the ribs appeared to have been chewed. What appeared to be rumen contents were found about 15 yards from the carcass and encompassed an area about 3 feet in diameter. [redacted] said that this cow was a Hereford. A white patch of fur was visible on the forehead. A presumptive wolf scat containing red hairs was observed approximately 20 yards from the cow carcass.

**Livestock Examination:**

- Calf – Rear legs (Figures 29-39):
    - Hemorrhage was apparent on the underside of the skin of the right rear leg between the tarsal and stifle joints (Figure 31). This lesion appeared more chronic in nature, compared to other indications of trauma described below, as the visual evidence suggested infection/abscessation in that region.
    - A second area of hemorrhage consistent with trauma that appeared more recent than that described above was observed between the skin and bone of one of the hind legs (Figure 34). The appearance of the wound was consistent with ante mortem injury, potentially a puncture due to what looked like the presence of tissue edema and air in the subcutaneous space. That said, no puncture wound was noted at that site.
    - Mr. Stiles noted a small hole (I visually estimated at approximately 0.2 inches in diameter) through the skin of a lower leg. I did not record whether this was the right or left hind leg of a calf. Mr. Stiles also reported another hole in the leg between the distal end of the tibia and fibula and the calcaneus. This hole was perpendicular to the long axis of the leg and its diameter was not measured.
- Both hind legs were examined by CDFW Environmental Scientist Pete Figura on 11/13/2015. He removed the skin of the right rear leg below the tarsal joint and noted that the infection extended down the metatarsus (Figure 40). Mr. Figura indicated that no significant marks/holes in the skin were found during his examination, nor did he find any substantial tissue damage beneath the skin on the right rear leg. Mr. Figura did not find any significant marks/holes on the skin or find any substantial damage beneath the skin of the left rear leg. He did report a small surface wound that he thought might have been an abrasion on/around one of the dew claws.
    - Photographs of both hind legs were examined by Dr. Deana Clifford and Ms. Jamie Rudd of CDFW's Wildlife Investigations Laboratory and their report is attached.

- Summary: Based on examination of physical and photographic evidence available for the calf, the cause of death could not definitively be determined.

- Cow – Skeletal remains and rumen contents (Figures 16-22):

  - The ends of some ribs appeared to have been chewed. No evidence of the cow being entangled in wire was observed. Bird feces (probable raptor or raven) were observed on a rock and log near the carcass. The rumen contents did not appear to have been disturbed and were distributed as an even layer on the ground. Almost no skin, hair, or muscle tissue was present.

  - Summary: Based on examination of the physical evidence available, the cause of death could not definitively be determined.

Siskiyou-01
November 11, 2015

**Classification of Reported Wolf Depredation Incident**

Reported wolf depredation incidents may be classified as either; confirmed, probable, possible/unknown, or other. These classifications are based on criteria used by other states, and USDA/APHIS Wildlife Services (see attached).

Based on the scene and physical evidence gathered at the scene, the Department has concluded cause of death on the calf:

Confirmed Wolf _____

Probable Wolf __X____

Possible/Unknown _____

Other _____

Based on the scene and physical evidence gathered at the scene, the Department has concluded cause of death on the cow:

Confirmed Wolf _____

Probable Wolf _____

Possible/Unknown ___X___

Other _____

Appendices:

1. California Department of Fish and Wildlife, Wildlife Investigations Laboratory - Non-Game Species Program Consultation Report.

2. US Department of Agriculture Wildlife Services: Criteria for Classification of Reported Depredation Incidents.



Figure 1. Location of wolf incident Siskiyou-01.

Figure 2. Calf discovered on the morning of 11/10/2015, when 5 wolves were reportedly seen feeding on the carcass. Photo provided by [redacted].



Figure 3. Photograph taken on 11/10/2015, of a wolf in the vicinity of where 5 wolves were reported feeding on a calf carcass that day. Photo provided by [redacted].

Figure 4. Three wolves photographed during site inspection on 11/11/2015. (R. Callas, CDFW photo).

Figure 5. Wolf photographed during the site inspection on 11/11/2015. (R. Callas, CDFW photo).

Figure 6. Wolf photographed during the site inspection on 11/11/2015. (R. Callas, CDFW photo).



Figure 7. Locations of broadcast calling, calf and cow remains, scats collected, and observations of wolves.

Figure 8. General area where a calf was reportedly fed upon by wolves on 11/10/2015.



Figure 9. Vicinity photograph from near the site where a calf was reportedly fed upon by wolves.

Figure 10. Area of blood near where 2 hind legs of a calf were found on 11/10/2015 (area outlined in yellow).



Figure 11. Area of blood near where 2 hind legs of a calf were found on 11/10/2015 (area outlined in yellow).

Figure 12. Blood in meadow where 5 wolves were reportedly observed feeding on a calf on 11/10/2015.

Figure 13. Bone fragments in the meadow where 5 wolves were reportedly observed feeding on a calf on 11/10/2015. A quarter was placed in the photograph for scale.

Figure 14. Scat collected within 50 yards of where a calf was reportedly fed upon by wolves.

Figure 15. Scat collected within 50 yards of where a calf was reportedly fed upon by wolves.

Figure 16. Cow carcass discovered on 11/11/2015, approximately 150 yards southeast of where 5 wolves were reportedly observed feeding on a calf on 11/10/2015.

Figure 17. Cow carcass discovered on 11/11/2015, approximately 150 yards southeast of where 5 wolves were reportedly observed feeding on a calf on 11/10/2015.




Figure 18. Lower jaw of a cow discovered on 11/11/2015, approximately 150 yards southeast of where 5 wolves were reportedly observed feeding on a calf on 11/10/2015.

Figure 19. Remains of cow discovered on 11/11/2015, approximately 150 yards southeast of where 5 wolves were reportedly observed feeding on a calf on 11/10/2015.




Figure 20. Cow carcass discovered on 11/11/2015, approximately 150 yards southeast of where 5 wolves were reportedly observed feeding on a calf on 11/10/2015.



Figure 21. Presumptive rumen contents from a cow discovered on 11/11/2015, approximately 150 yards southeast of where 5 wolves were reportedly observed feeding on a calf on 11/10/2015.

Figure 22. Presumptive rumen contents from a cow discovered on 11/11/2015, approximately 150 yards southeast of where 5 wolves were reportedly observed feeding on a calf on 11/10/2015.



Figure 23. Woody debris near the cow carcass discovered on 11/11/2015.

Figure 24. Woody debris near the cow carcass discovered on 11/11/2015.

Figure 25. Disturbed rock near a cow carcass discovered on 11/11/2015.

Figure 26. Possible hoof scrape marks on a log near a cow carcass discovered on 11/11/2015.

Figure 27. Cattle trail where a wolf track was discovered on 11/11/2015.

Figure 28. Possible wolf track near a cow carcass discovered on 11/11/2015.

Figure 29. Rear legs of a calf collected by [redacted] on 11/10/2015.

Figure 30. Right rear leg (top) and left rear leg (bottom) of a calf collected by [redacted] on 11/10/2015.

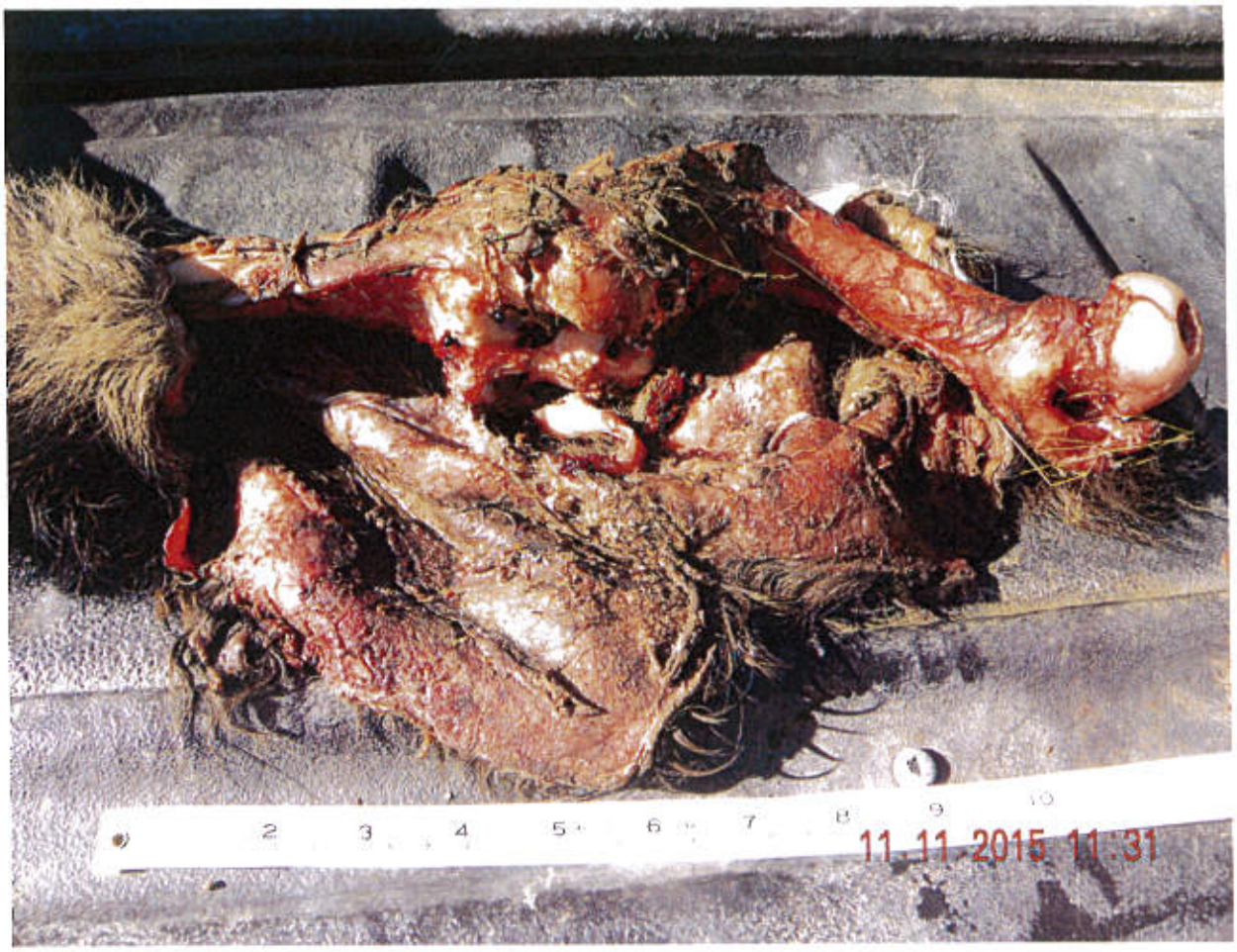


Figure 31. Right rear leg of a calf collected by [redacted] on 11/10/2015.

Figure 32. Right rear leg of a calf collected by [redacted] on 11/10/2015. This leg was swollen compared to the other leg collected. A lesion was present at the tarsus.

Figure 33. Right rear leg (with measuring tape for scale) of a calf collected by [redacted] on 11/10/2015.

Figure 34. Rear leg of a calf collected by [redacted] on 11/10/2015.

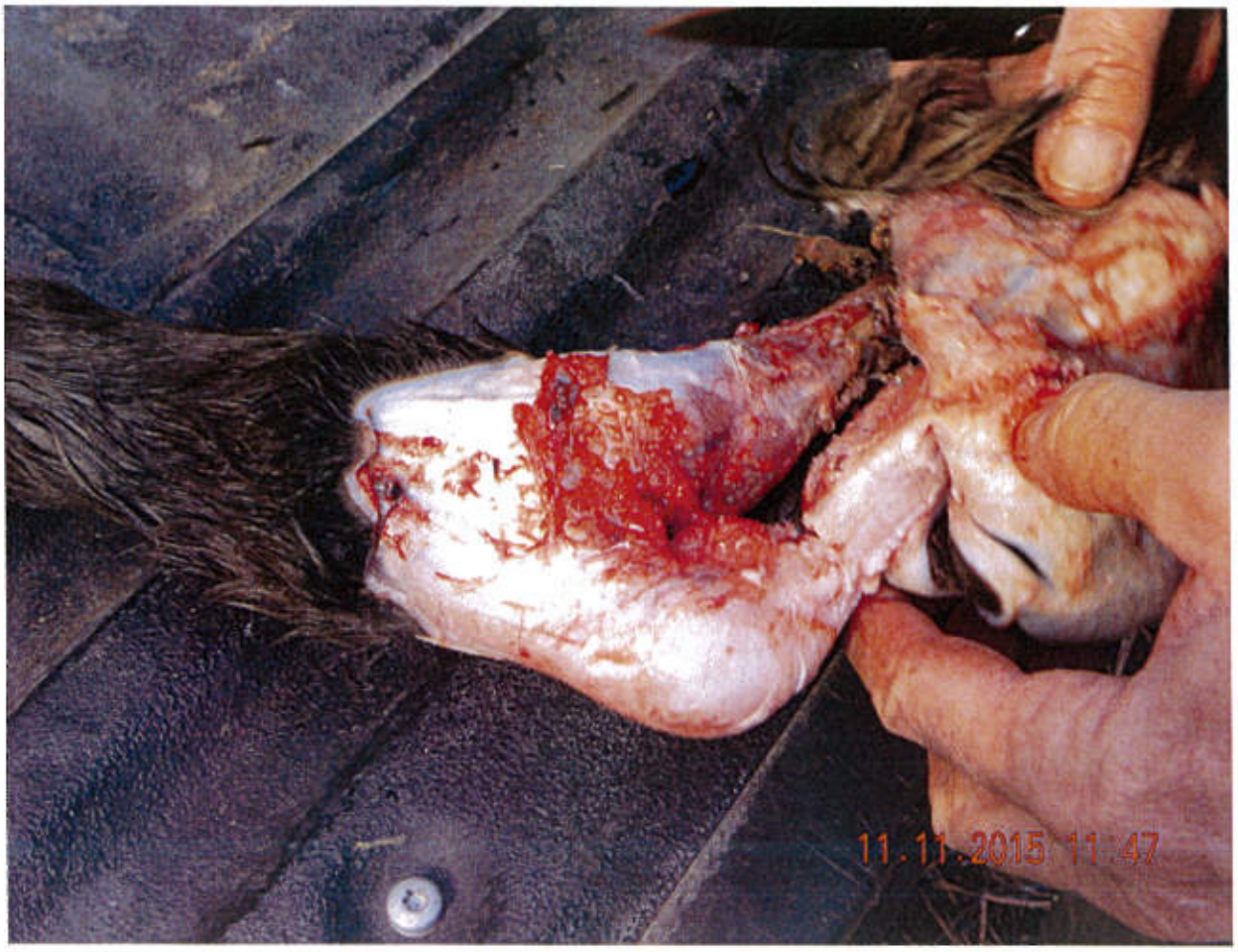


Figure 35. Left rear leg of a calf collected by [redacted] on 11/10/2015.

Figure 36. Left rear leg of a calf collected by [redacted] on 11/10/2015.

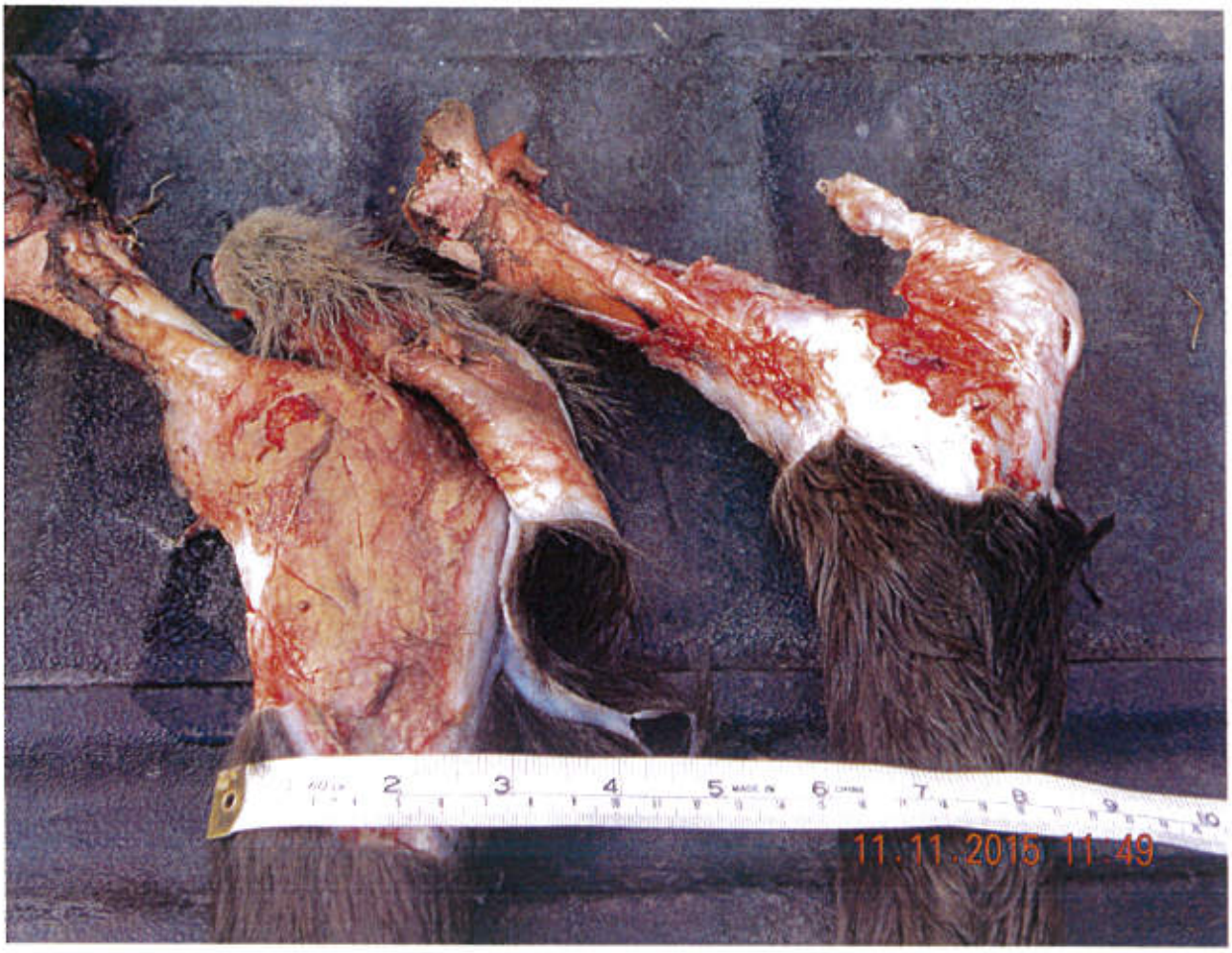


Figure 37, Right rear leg (image on left) and left rear leg (image on right) of a calf collected by [redacted] on 11/10/2015. Leg on left appears infected.

Figure 38. Right rear leg of a calf with an apparent infection.

Figure 39. Right rear leg of a calf with an apparent infection extending from the tarsal joint down the metatarsus.

Siskiyou-01
November 11, 2015

**Appendix 1.**

**California Department of Fish & Wildlife – Wildlife Investigations Laboratory**

**Non-Game Species Program**

**Consultation Report**

FINDINGS MAY NOT BE DISTRIBUTED OR PUBLISHED WITHOUT CDFW & PATHOLOGIST PERMISSIONS

**- FINAL RESULTS -**

| | |
|---|---|
| **WIL # / Necropsy #:** n/a | **Species:** Cow (*Bos taurus*) |
| **Animal ID:** none | **Sex:** unk |
| **City / County / State:** CA | **Post Mortem Condition:** Moderate autolysis based on photos only |
| **Requester Information:**<br><br>Richard Callas, R1, CDFW | **Department Contacts:**<br><br>1) Dr. Deana Clifford, Wildlife Veterinarian<br><br>(916) 358-2378; deana.clifford@wildlife.ca.gov<br><br>2) Jaime Rudd, Environmental Scientist, 916-358-2378; Jaime.rudd@wildlife.ca.gov |

Clinical History: Consult to describe and interpret any lesions/findings observed in photographs taken of the partial remains of domestic cattle calf requested of WIL veterinarian and nongame program necropsy lead ES. (you can fill this in or refer to your report), or just excerpt from below.

Summary of Observations Based on Photographs Provided: Two hind limbs were recovered from the calf and available for photographic examination. The subcutaneous tissue of the right rear leg at the tarsus appears to have a large, irregular laceration with corresponding hemorrhage to the underlying surface, consistent in appearance with an ante-mortem injury (the size of which cannot be determined in the photo). Grossly, this injury appears to be older because the margins of the lesion appear thickened and granulated and the hemorrhage is in various stages of color change. There is also what appears to be caseous (having a cheese-like appearance) material in the central portion of the leg injury which would be indicative of a longer term infection/abscess, however this is presumptive and cannot be confirmed. It also cannot be determined if this wound was necrotizing or in the

process of properly healing without physical examination of tissues. The lack of skeletal muscle in the photograph precludes determining the extent of the infection.

The second hind leg has what appears to be a moderate to large subcutaneous hemorrhage (Figure 34). However, it is unclear if this hemorrhage is confined to the skin or if it extends into the underlying skeletal muscle. The hemorrhage appears recent and presumably occurred ante-mortem due to what looks like local edema and subcutaneous emphysema (air trapped under the skin) indicative of blunt, penetrating trauma. However, the evaluation of this wound is presumptive given the very limited ability to grossly diagnose wounds from a picture. There is no puncture that can be accurately appreciated with this photo and there is no scale in the photo, other than an unknown individual's hand, to accurately judge the size of this wound.

**Laboratory Findings/Diagnosis:** Cause of death: undetermined

**Comments:** In summary, the hind limbs presented in these photos appear to be in differing stages of injury that occurred ante-mortem. The lack of any tissues for histological examination and the absence of the majority of the carcass and additional tissues precludes determination of a cause of death.

Although it is possible that the right leg wound (Fig 34) was infected and necrotizing (in process of tissue death) and the calf had septicemia (blood infection) from the bacteria, or was in a process of healing, without additional skeletal muscle and other tissues to examine both grossly and microscopically (histologically), this cannot be determined.

The second picture with hemorrhage appears to have been ante-mortem and occurred more recently. Based on the photograph this wound alone does not appear large enough to have killed the animal, however it does appear to have occurred more recently than the other wound. If there is in fact emphysema (abnormal air presence) in the skin (as suggested by photographic appearance), this finding would be consistent with penetrating trauma because air could have been introduced into the tissue under the skin.

---

Photographs reviewed and report compiled by: Dr. Deana Clifford and Jaime Rudd, CDFW on 11/19/2015

Pathologist review: N/A (no tissues available for necropsy and histology)

**Appendix 2.**

USDA Wildlife Services 2003

## CRITERIA FOR CLASSIFICATION OF REPORTED DEPREDATION INCIDENTS

Reported wolf, bear, or lion depredation incidents should be classified as either confirmed, probable, possible/unknown, or other, based on the following criteria. For MIS reporting purposes, "reported" damage may often include incidents described as probable, possible/unknown, and/or other, if the cooperated first reported these incidents as predation.

CONFIRMED - Depredation is confirmed in those cases where there is reasonable physical evidence that an animal was actually attacked and/or killed by a predator. The primary confirmation factor would ordinarily be the presence of bite marks and associated subcutaneous hemorrhaging and tissue damage, indicating that the attack occurred while the victim was alive, as opposed to simply feeding on an already dead animal. Spacing between canine tooth punctures, feeding pattern on the carcass, fresh tracks, scat, hairs rubbed off on fences or brush, and/or eye witness accounts of the attack may help identify the specific species or individual responsible for the depredation. Predation might be confirmed on the absence of bite marks and associated hemorrhaging (i.e., if much of the carcass has already been consumed by the predator or scavengers) if there is other physical evidence to confirm predation on the live animal. This might include blood spilled or sprayed at a nearby attack site or other evidence of an attack or struggle. There may also be nearby remains of other victims for which there is still sufficient evidence to confirm predation, allowing reasonable inference of confirmed predation on the animal that has been largely consumed.

PROBABLE - Having some evidence to suggest possible predation, but lacking sufficient evidence to clearly confirm predation by a particular species, a kill may be classified as probably depending on a number of other factors such as: (1) Has there been any recently confirmed predation by the suspected depredating species in the same or nearby area? (2) How recently had the livestock owner or his employees observed the livestock? (3) Is there evidence (telemetry monitoring data, sightings, howling, fresh tracks, etc.) to suggest that the suspected depredating species may have been in the area when the depredation occurred? All of these factors, and possibly others, should be considered in the investigator's best professional judgment.

POSSIBLE/UNKNOWN - Lacking sufficient evidence to classify an incident as either confirmed or probable predation, the possible/unknown classification is appropriate if it is unclear what the cause of death may have been. The investigator may or may not have much of a carcass remaining for inspection, or the carcass may have deteriorated so as to be of no use. The investigator would want to consider if the area has been frequented by a predator, or if the habitat is one which the predator is likely to use. Possible predation may include cases there counts show that abnormal numbers of livestock are missing or have disappeared above and beyond past experience, and where other known cases of predation have occurred previously in the area.

OTHER - Cause of livestock deaths should be classified as other when it is discovered that the cause of death was not likely caused by the animal reported to Wildlife Services during a request for assistance. Examples of other may include cases where the cause of death is confirmed or is likely due to predation by some other animal or cause determined at the time of the investigation such as red fox instead of a coyote or other causes such as, bloat, poisonous plants, stillborn, disease, lightening strike, vehicle collision, etc. If the specific other cause of death can be determined, it should be written in the space provided for other.