



CCR 679 Wildlife Rehabilitation

- Attachment 9

Compilation of Photographic Evidence
of Violations or Deficiencies.

California Department of Fish and Wildlife 2024






Figure 1. Sharp objects (indicated with red circles) on the interior of bird aviaries: zip ties (A), hardware cloth (B), and roof nails (C).



Figure 2. Outdoor small mammal enclosure that shows accumulated fecal matter under the cage (insert closeup of waste). This was an unoccupied enclosure that had been empty for several weeks.

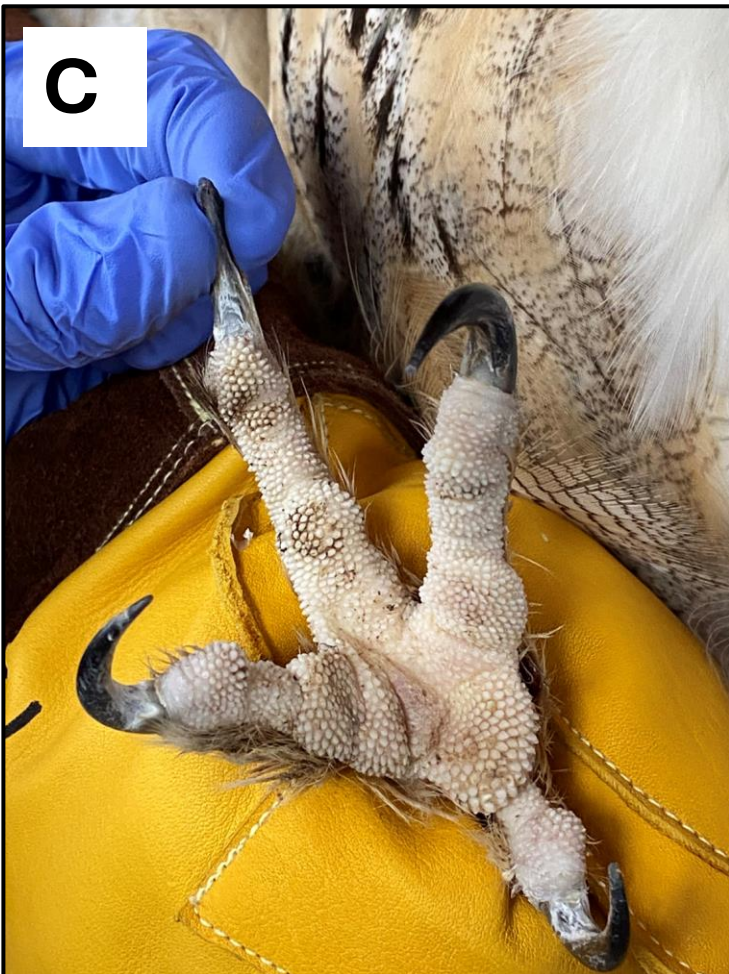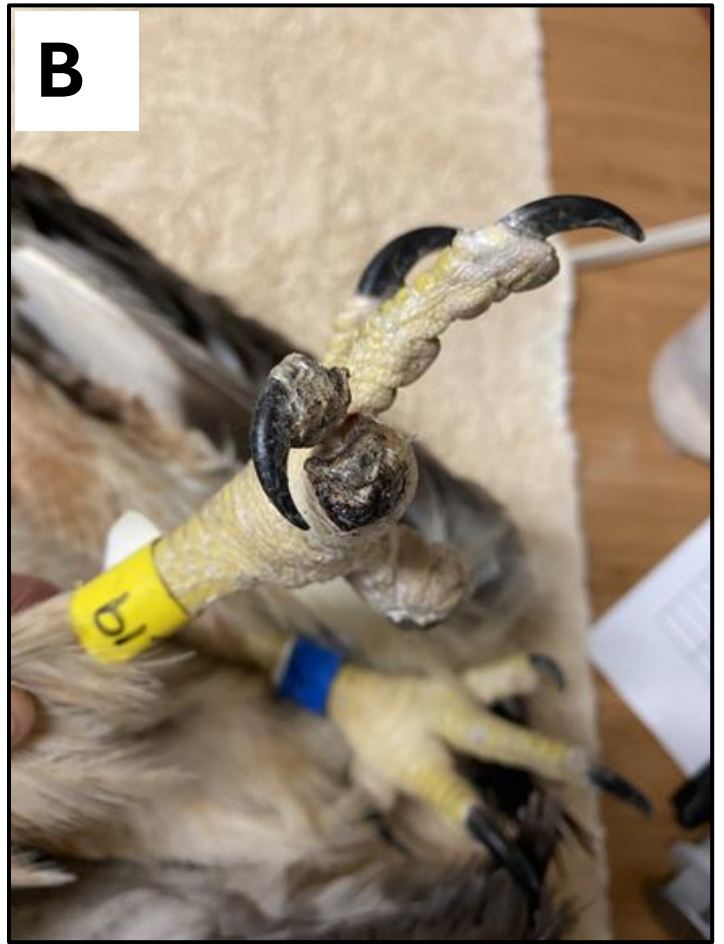

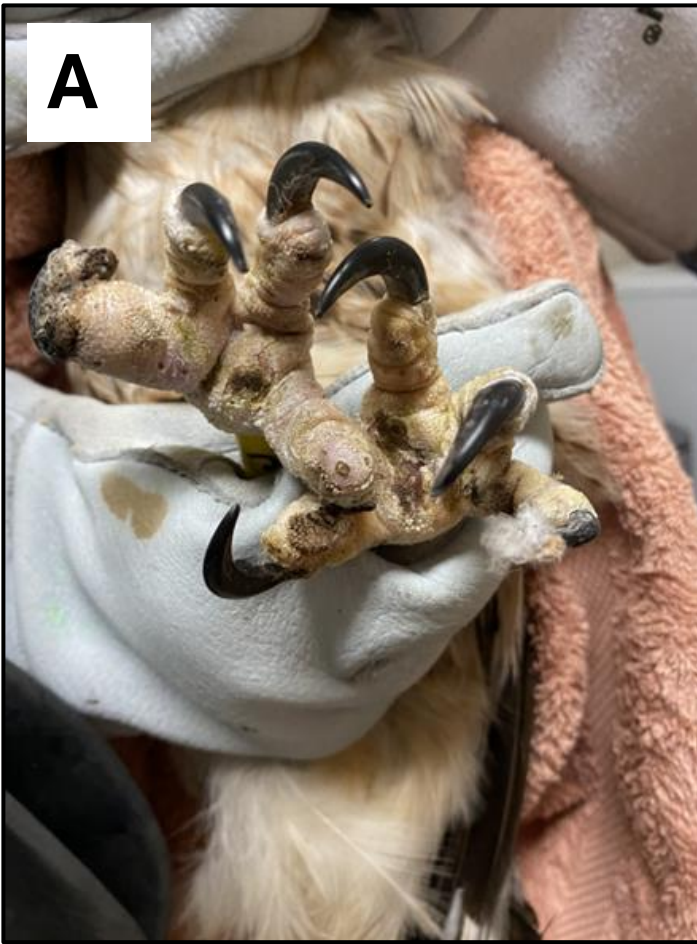
Figure 3. Poor husbandry (improper perches) impacting raptor feet: bumble foot lesions (A), missing digits and necrotic digit (B), and healthy foot for comparison (C).





Figure 4. Raccoons housed inside a kitchen without any visual barrier which could cause habituation and mal-imprinting, cage is inappropriate size for pre-release conditioning, and biosecurity issues for human safety regarding raccoon roundworm.

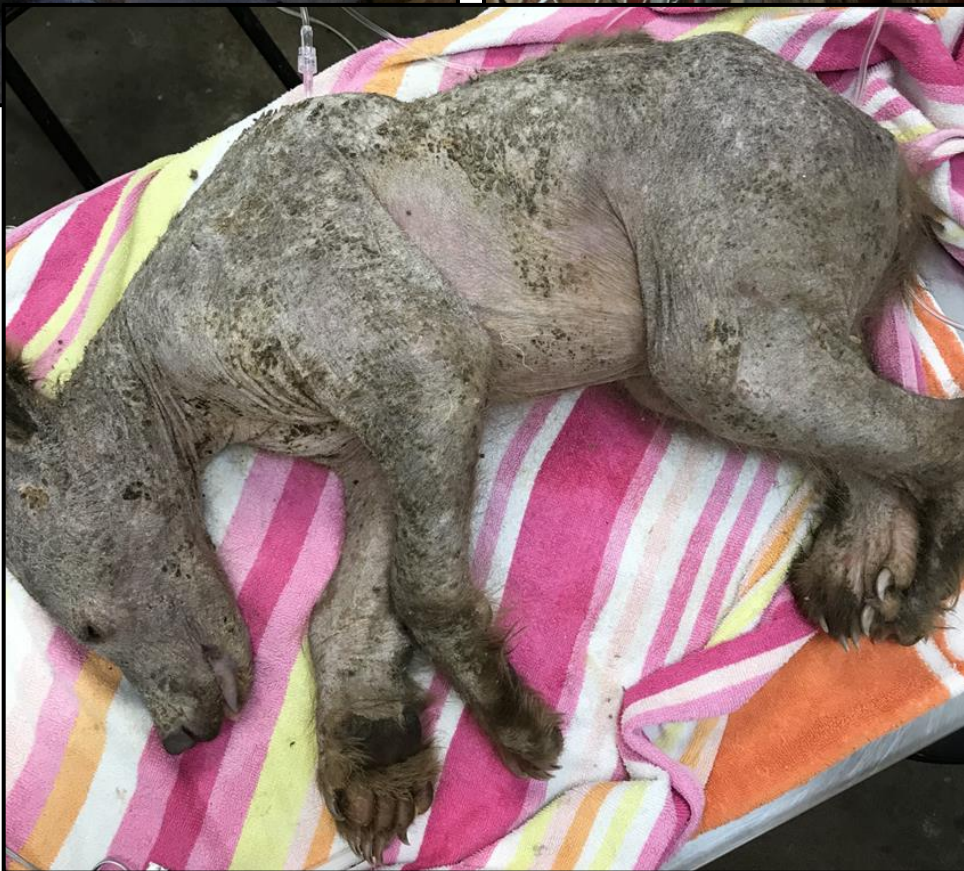

Figure 5. Black bear cub inside a sub-permittee (satellite facility) house, images show severe skin disease not being treated properly, animals were never reported to the Department.

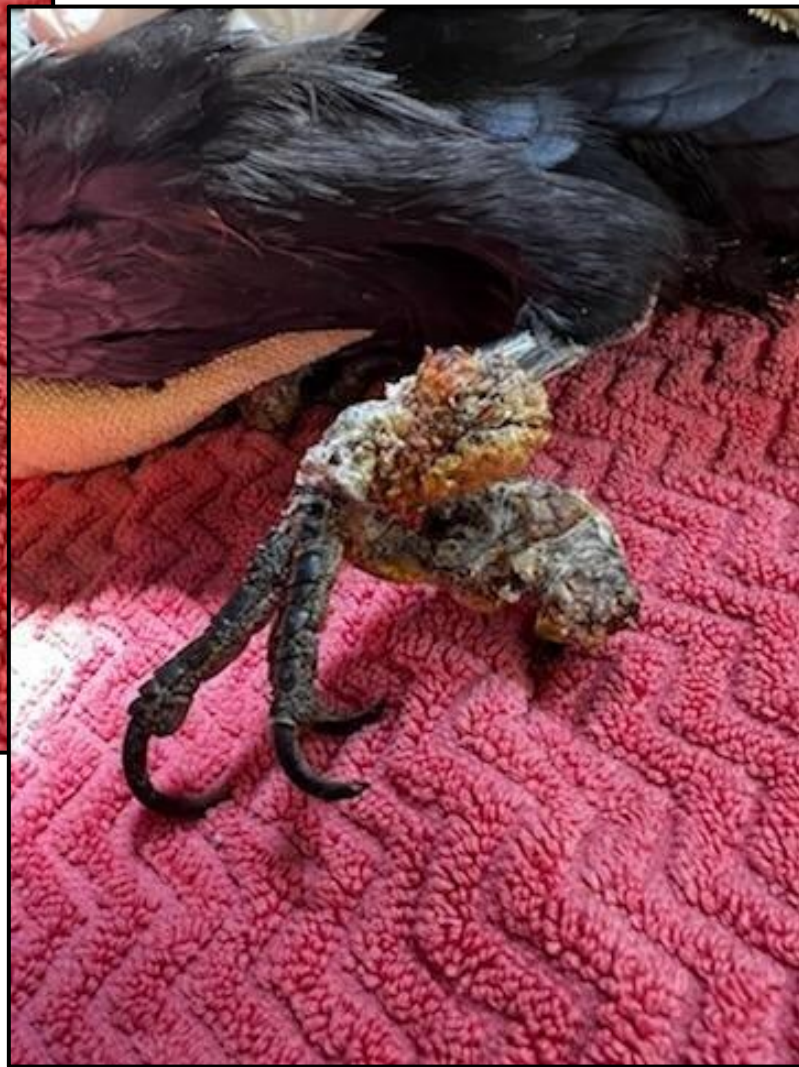

Figure 6. Avian pox on Corvid feet – example of improper triage and biosecurity practices.

A**B**

Figure 7. Aviary enclosures that does not prevent animal ingress or egress: Gaps (red circles) on side (A) and top (B) enclosure materials.



Figure 8. Mixing of domestic animals with wildlife. This image shows domestic waterfowl with wild waterfowl.

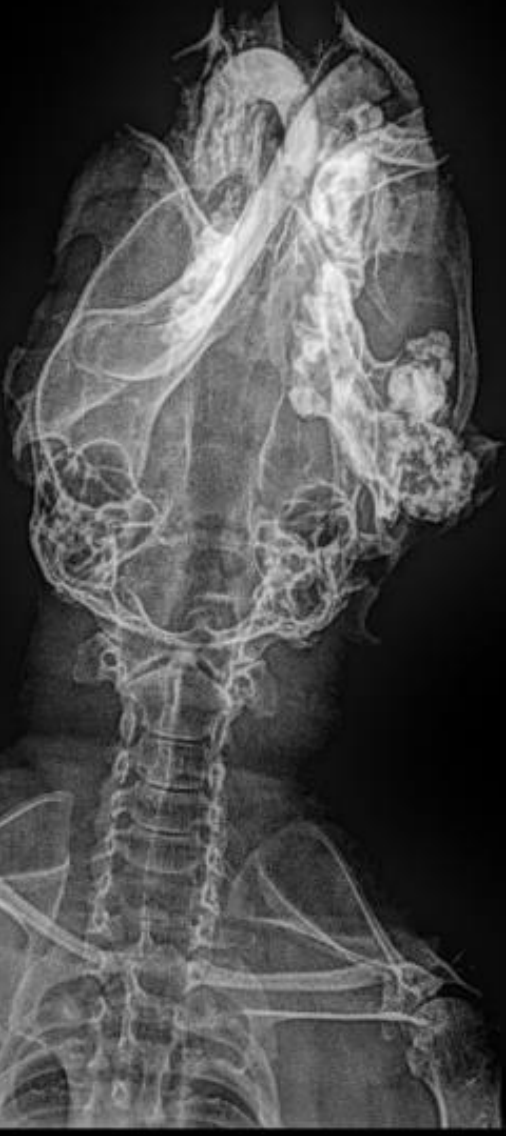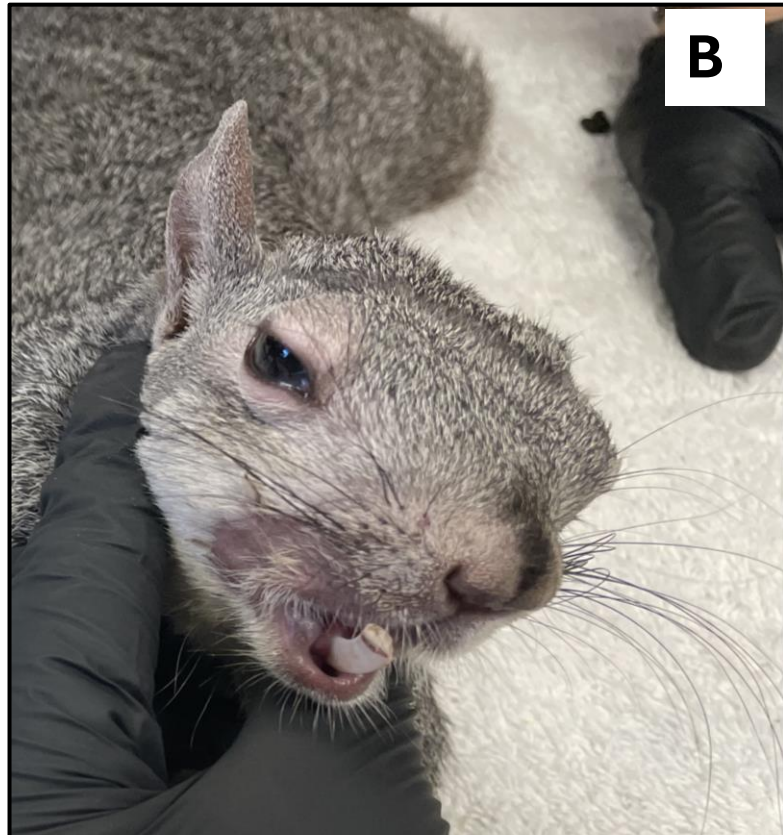
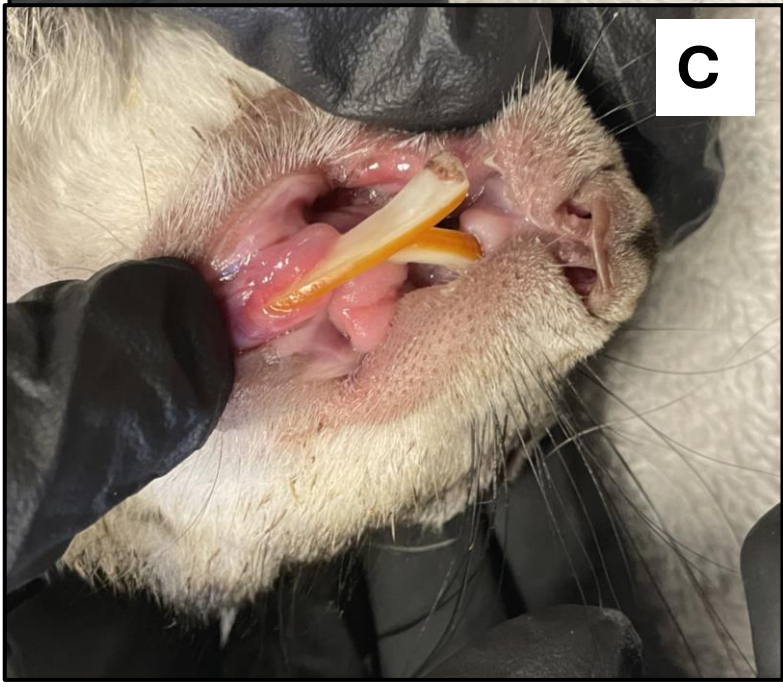A**B****C**

Figure 9. Ground squirrel improperly treated while being temporarily possessed causing maligned teeth: x-ray showing right side chronic infection and overgrown teeth (A) chronic pain (B), and improperly worn teeth (C).

